

# Isolated “Blow Out” Jejunal Perforation Following Blunt Abdominal Trauma- Experience of Two Cases

B.V. GOUDAR, UDAY AMBI, Y. LAMANI, SUNIL TELKAR

## ABSTRACT

Small bowel injury following blunt abdominal trauma has been widely reported. Isolated jejunal perforation which is caused by blunt abdominal trauma is rare and is most often seen in road traffic accidents. Here, we present two cases of isolated jejunal perforation due to raised intra abdominal pressure in the form of abdominal tightening by the dhoti after it was caught in the

belt of an engine and a fall from the stairs while stepping down. Explorative laparotomy revealed the slit-like perforation on the anti mesenteric border. Early surgical intervention led to good recovery in both the cases. A high index of suspicion, repeated clinical examination and the proper utilization of investigational tools definitely helped us in managing these kinds of rare cases.

**Key Words:** Jejunum, Perforation, Blunt Trauma

## INTRODUCTION

Small bowel injury following blunt abdominal trauma is the commonest presentation in road traffic accidents. The isolated blowout perforation of the jejunum is extremely rare. We came across two cases of isolated jejunal perforations following blunt abdominal injury during 2010–2011 in our hospital.

Samuel Annan reported the first case of intestinal perforation following blunt abdominal trauma in 1837 [1]. Punctate or slit like perforations often occurring on the anti mesenteric border are probably the consequence of a sudden increase in the intraluminal pressure in a fluid or air filled loop. Robbs et al. [2], in 1980, reported five such lesions in Zulu tribesmen, which were mostly caused by a blow to the abdomen with a heavy, round-headed weapon. These perforations were not surrounded by damaged tissue and did not appear to result from a crushing type injury [2, 3]. They are referred to as “blowout” perforations. These perforations may be missed initially and may become apparent around three days after the injury [4]. or bowel ischaemia which is secondary to contusion, leading to stricture and delayed perforation occurs after 4 weeks. The two cases were reported almost 2 months following blunt abdominal trauma [5].

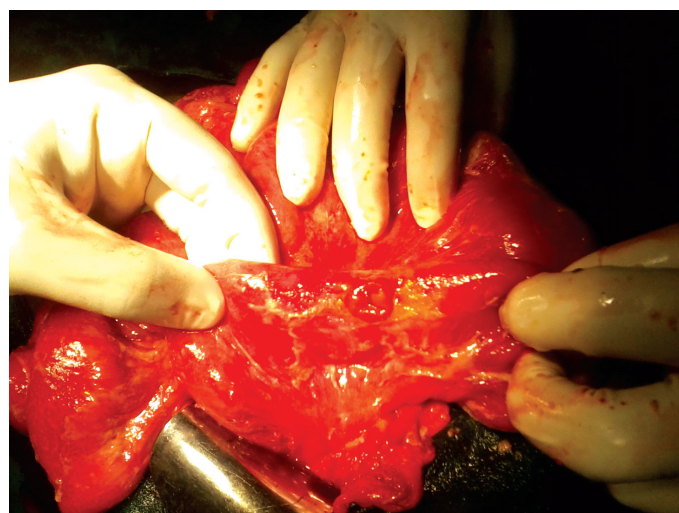
## CASE REPORTS

### CASE-1

A 34-year old male patient was admitted to the hospital with intense abdominal pain after his dhoti was caught in the wheel belt of the engine while working in the field. Bruise marks were noted in the flanks. Palpation revealed tenderness and guarding all over the abdomen. Liver dullness was obliterated and free fluid was noted. Bowel sounds were absent. His blood parameters were normal. The erect abdomen showed gas under the diaphragm. Ultrasound of the abdomen revealed free fluid in the peritoneum. Written informed consent was obtained from him.

Laparotomy revealed bile stained fluid and an isolated perforation which was sized 2cms in the jejunum, on the anti mesenteric border,

25 cms distal to the ligament of Treitz was seen [Table/Fig-1]. The rest of the bowel and other organs were normal. The perforation was closed primarily. The postoperative course was uneventful.

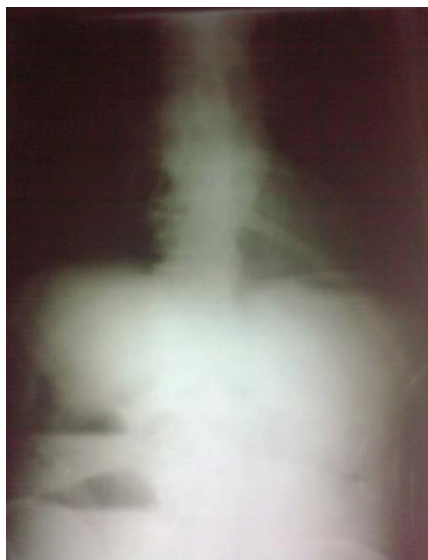

**[Table/Fig-1]:** Isolated jejunal perforations following blunt abdominal trauma

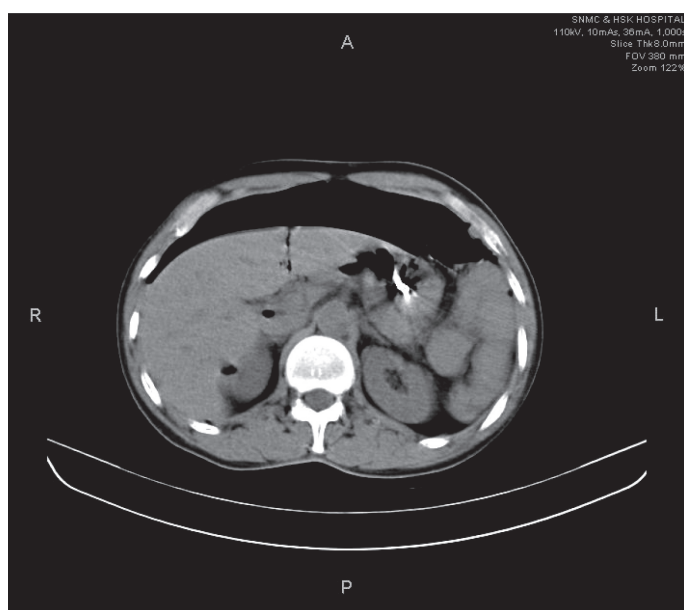
### CASE-2

A 45-year old female patient was admitted to the hospital with a history of fall from the stairs. The patient had intense abdominal pain and vomiting. The patient was in hypotension and had tachycardia. Her abdomen was slightly distended and tenderness was present. Her blood parameters revealed leucocytosis. The erect X-ray of the abdomen did not show free gas [Table/Fig-2], but ultrasonography and CT revealed free gas and fluid in the peritoneum [Table/Fig-3]. The patient consented for the surgery.

The laparotomy of the patient showed isolated jejunal perforation with bile stained fluid. The perforation was along the longitudinal axis of the anti mesenteric border and 20cms away from the ligament of Treitz. No other injury was seen. The ruptured jejunum was sutured primarily.



[Table/Fig-2]: X-ray erect abdomen showing no free gas under diaphragm



[Table/Fig-3]: CT abdomen shows free air and fluid in the peritoneum

## DISCUSSION

Seventy-five percent of the blunt abdominal trauma cases are caused by motor vehicle accidents [1]. Although small bowel injuries have been reported to be the third most common injuries in blunt abdominal trauma, they occur in less than 1% of the blunt trauma patients [6, 7]. The mechanisms of small bowel injuries with blunt trauma include shearing forces, compression between the abdominal wall and the vertebral column and bursting injury due to a sudden increase in the intraluminal pressure. The isolated "blowout type" of rupture of the jejunum following constriction by a dhoti or fall from the stairs is extremely uncommon. This leads to a sudden increase in the intra-abdominal pressure, which in association with a full stomach, can lead to this kind of perforation. A similar mechanism of small bowel injury was caused by physical assault [8] and knee kick [9] during a game of foot ball.

Physical examination is not adequate on its own for the diagnosis of such cases, and it was found to be reliable in only 30% of the blunt trauma cases [7]. Fakhry et al [10] observed that 67.7% out of 198 patients with blunt small bowel injury, initially presented with signs or symptoms which were highly suggestive of perforative peritonitis and 84.3% were taken to the operating room without delay. X ray

of the erect abdomen, USG, diagnostic peritoneal lavage and CT of the abdomen are most commonly used diagnostic aids other than physical examination. In the first case, the diagnosis of the hollow viscous perforation was not problematic, but in the other case, the persistent physical findings forced us to opt for CT of the abdomen. CT of the abdomen definitely helped us in the diagnosis. According to Burney et al [11], peritoneal lavage has proven to be sensitive for the demonstration of the haemoperitoneum, but it was found to be less reliable in the early diagnosis of intestinal injuries. The gold standard for the assessment of blunt trauma diagnosis is C T scanning, with a sensitivity of 92% and a specificity of 94% [12]. In recent times, laparoscopy has played an important role in the diagnosis as well as in the treatment of blunt abdominal trauma. Diagnostic laparoscopy should be preferred instead of diagnostic peritoneal lavage in relatively haemodynamically stable patients. Most of the patients will be having punctuate or slit like perforations on the anti mesenteric border and so, ideally they require laparotomy and the primary closure of the perforation, with peritoneal lavage. Now, with the advent of laparoscopy, it is possible to close the perforation by using endosutures or staplers [13]. Small bowel perforation has low mortality and complication rates if it is treated before 24 hours after the injury [8]. Delayed jejunal perforation is often associated with high mortality and morbidity. Since 1990, 9 cases of isolated jejunal perforations have been reported [Table/Fig-4], but the nature of the injury which was seen in our cases was different.

Serial number	Year	Author	Number of cases	Nature of injury
1	1993	W K Chiang et al	1	Blunt injury
2	1994	J M Lindenmann et al	1	Blunt injury
3	2004	H Razali et al	1	Blunt injury
4	2006	I A Munshi et al	1	Blunt injury
5	2007	A K Coskun et al	1	Knee kick
6	2010	Kostantinidis C et al	1	Physical assault
7	2010	A Baccoli et al	3	Blunt injury

[Table/Fig-4]: Review of isolated jejunal perforation following blunt abdominal trauma from 1990.

Clinical observation was not sufficient to justify the diagnosis and so the pre operative diagnosis of isolated jejunal perforation was definitely challenging. A high index of suspicion, repeated clinical examinations and the utilization of imaging modalities really helped us to diagnose these kinds of clinical entities.

## ACKNOWLEDGMENT

We would like to thank Dr A S Mallapur, Principal and Dr E B Kalburgi Professor and Head, Dept. of Surgery, S N Medical College and HSK Hospital, Bagalkot for the valuable support that they rendered for preparing this article.

## REFERENCES

- [1] Griswold RA, Collier HS. Blunt abdominal trauma. *Int Abstr Surg* 1961;112:309-29.
- [2] Robbs JV, Moore SW, Pillay SP. Blunt abdominal trauma with jejunal injury: a review. *J Trauma* 1980; 20:308-11.
- [3] Dauterive AH, Flancbaum L, Cox EF. Blunt intestinal trauma. A modern day review. *Ann Surg* 1985; 201:198-203.
- [4] Sule AZ, Kidmas AT, Awani K, Uba F, Misauno M. Gastrointestinal perforation following blunt abdominal trauma. *East Afr Med J* 2007; 84:429-33.
- [5] Subramanian V, Raju RS, Vyas FC, Joseph P, Sitaram V. Delayed jejunal perforation following blunt abdominal trauma. *Ann R Coll Surg Engl* 2010; 92:23-24.

- [6] Guarino J, Hassett JM Jr, Luchette FA. Small bowel injuries: mechanisms, patterns, and outcomes. *J Trauma* 1995; 39:1076-80.
- [7] Allen GS, Moore FA, Cox CS Jr, Wilson JT, Cohn JM, Duke JH. Hollow visceral injury and blunt trauma. *J Trauma* 1998; 45:69-78.
- [8] Kostantinidis C, Pitsinis V, Fragulidis G. Isolated jejunal perforation following blunt abdominal trauma. *Ulus Travma Acil Cerrahi Derg* 2010; 16:87-89.
- [9] Lindenmann JM, Schmid D, Akovbiantz A. Jejunal perforation following blunt abdominal trauma. *Schweiz Rundsch Med Prax* 1994; 83:857-60.
- [10] Fakhry SM, Brownstein M, Watts DD, Baker CC, Oller D. Relatively short diagnostic delays [8 hours] produce morbidity and mortality in blunt small bowel injury: an analysis of time to operative intervention in 198 patients from a multicenter experience. *J Trauma*. 2000; 48:408-15.
- [11] Burney RE, Mueller GL, Coon WW, Thomas EJ, Mackenzie JR. Diagnosis of isolated small bowel injury following blunt abdominal trauma. *Ann Emerg Med* 1983; 12:71-74.
- [12] Sherck J, Shatney C, Sensaki K, Selivanov V. The accuracy of computed tomography in the diagnosis of blunt small bowel perforation. *Am J Surg* 1994; 168:670-75.
- [13] Townsend MS, Peltas ME. A technique for the rapid closure of traumatic small intestinal perforation without resection. *Am J Surg* 1992; 164:171-72.

**AUTHOR(S):**

1. Dr. B.V. Goudar, MS
2. Dr. Uday Ambhi, MD
3. Dr. Y. Lamani, MS
4. Dr. Sunil Telkar, MS

**PARTICULARS OF CONTRIBUTORS:**

1. Associate Professor, Dept. of Surgery, SN Medical College and HSK Hospital, Bagalkot, Karnataka, India.
2. Assistant Professor, Dept. of Anaesthesiology, SN Medical College and HSK Hospital, Bagalkot, Karnataka, India.
3. Assistant Professor, Dept. of Surgery, SN Medical College and HSK Hospital, Bagalkot, Karnataka, India.
4. Assistant Professor, Dept. of Surgery, SN Medical College and HSK Hospital, Bagalkot, Karnataka, India.

**NAME, ADDRESS, TELEPHONE, E-MAIL ID OF THE CORRESPONDING AUTHOR:**

Dr. B V Goudar  
Associate Professor, Dept. of Surgery,  
SN Medical College and HSK Hospital,  
Bagalkot, Karnataka, India-587101.  
Telephone: +918354-235400  
E-mail: drbvgoudar@yahoo.co.in

**DECLARATION ON COMPETING INTERESTS:**

No competing Interests.

There are no external funding, financial interests and conflicts of interest involved in this study.

Date of Submission: **May 31, 2011**

Date of peer review: **Jul 26, 2011**

Date of acceptance: **Aug 08, 2011**

Online first: **Aug 17, 2011**

Date of Publishing: **Oct 05, 2011**